

## LAPAROSCOPIC TREATMENT OF GENITOURINARY FISTULAE

Roberto Garza Cortés, Rafael Clavijo and Rene Sotelo.

Robotic and Minimal Invasive Surgery Center. CIMI. Caracas. Venezuela.

**Summary.-** We present the laparoscopic management of genitourinary fistulae, mainly five types of fistulae, vesicovaginal, ureterovaginal, vesicouterine, rectourethral and rectovesical fistula. Vesicovaginal fistula (VVF) is mostly secondary to urogynecologic procedures in developed countries, abdominal hysterectomy being the main cause of this condition; they represent 84.9% of the genitourinary fistulae (1). Management has been described for this type of fistula, where low success rate (7-12%) has been reported. Ureterovaginal fistulas may occur following pelvic surgery, particularly gynecological procedures, or as a result of vaginal foreign bodies or stone fragments after shock wave lithotripsy, patients typically present with global and persistent urine leakage

through the vagina, this causes patient discomfort, distress, and typically protection is used to stay dry, the initial management is often conservative but typically fails. Vesicouterine fistula is a rare condition that only occurs in 1 to 4% of genitourinary fistulas, the primary cause is low segment cesarean section, and clinically presents in three different forms, which will be described. Treatment of this type of fistulae has been conservative, with hormone therapy and surgery, depending on the presenting symptoms. Recto-urinary (rectovesical and rectourethral) fistulae (RUF) are uncommon and can be difficult to manage clinically. Although they may develop in patients with inflammatory bowel disease and perirectal abscesses, rectourethral fistula frequently result as an iatrogenic complication of extirpative or ablative prostate procedures. Rectovesical fistula usually develops following radical prostatectomy, and occurs along the vesicourethral anastomotic line or along the suture line of a posterior "racquet-handle" closure of the bladder. Conservative management consisting of urinary diversion, broad-spectrum antibiotics and parenteral nutrition is often initially attempted but these measures often fail. Timing of repair is often individualized mainly according to the etiology, delay of diagnosis, size of fistula, the first or subsequent repairs, and the general condition of the patient. Different surgical techniques for the management of RUF have been reported. Encouraged by our experience in minimally invasive surgery we present the laparoscopic approach.



### CORRESPONDENCE

Rene Sotelo and Roberto Garza  
Instituto Médico La Foresta  
Av. Principal.  
Urb. La Foresta. Anexo B piso 2  
Caracas. (Venezuela)

robertogc2@gmail.com  
renesotelo@mac.com

Accepted for publication: March 5<sup>th</sup>, 2012

**Keywords:** Vesicovaginal fistula. Ureterovaginal fistula. Vesicouterine fistula. Rectourinary fistula. Rectourethral fistula. Rectovesical fistula. Laparoscopic management of genitourinary fistulae.

**Resumen.-** Presentamos el manejo laparoscópico de fístulas genitourinarias, principalmente cinco tipos de fístulas, vesico-vaginal, uretero-vaginal, vesico-uterina, recto uretral y recto vesical. La fístula vesico-vaginal

(FVV) es secundaria principalmente a procedimientos de uroginecología en los países desarrollados, siendo la principal causa de esta enfermedad la histerectomía abdominal, que representa un 84,9% de las fístulas genitourinarias (1). Se ha publicado el bajo índice (7-12%) de éxito en el manejo de este tipo de fístula. Las fístulas uretero-vaginales pueden presentarse después de cirugía pélvica, especialmente procedimientos ginecológicos, o como resultado de cuerpos extraños en la vagina o fragmentos litiasicos residuales después de la litotricia. Estos pacientes presentan típicamente pérdidas globales y persistentes de orina a través de la vagina, esto provoca molestias y angustia al paciente, el tratamiento inicial es conservador, pero a menudo insuficiente. La fístula vesico-uterina es una enfermedad rara que sólo ocurre entre el 1 al 4% de las fístulas genitourinarias, la causa principal es la cesárea del segmento bajo. Se presenta clínicamente de tres formas diferentes, que se describirán. El tratamiento de este tipo de fístulas ha sido conservador, con la terapia hormonal y cirugía, dependiendo de los síntomas presentes. Las fístulas recto urinarias (recto vesical y recto uretral) (FRU) son poco comunes y pueden ser difíciles de manejar clínicamente. A pesar de que se pueden desarrollar en pacientes con enfermedad inflamatoria intestinal y abscesos peri rectales, las fístulas recto uretrales se producen con frecuencia como una complicación iatrogénica de procedimientos de próstata. La fístula recto vesical generalmente se desarrolla después de prostatectomía radical, y se produce a lo largo de la línea anastomótica vesico-uretral o a lo largo de la línea de sutura de un cierre posterior (raqueta posterior) de la vejiga. Frecuentemente, se intenta un tratamiento conservador consistente en derivación urinaria, antibióticos de amplio espectro y nutrición parenteral, pero estas medidas fallan a menudo. El tiempo de reparación es a menudo individualizado de acuerdo principalmente con la etiología, el retraso de diagnóstico, el tamaño de la fístula, las primeras o posteriores reparaciones, y el estado general del paciente. Se han publicado diferentes técnicas quirúrgicas para el manejo de la FRU, presentamos el abordaje laparoscópico, alentados por nuestra experiencia en cirugía mínimamente invasiva.

**Palabras clave:** Fístula vesico-vaginal. Fístula uretero-vaginal. Fístula vesico-uterina. Fístula recto-urinaria. Fístula recto-uretral. Fístula recto-vesical. Manejo laparoscópico de fístulas genitourinarias.

## INTRODUCTION

Vesicovaginal fistulae (VVF) may be treated by different surgical techniques, which can be applied transvaginally or transabdominally (transvaginal or transvesical). In a study with a population of 11959

patients, 278 were admitted presenting genitourinary fistula, being the vesicovaginal the most frequent diagnosed in 236 patients (1). Surgeon preference often has an influence on which method is used. However, there is still controversy over the ideal approach and time of repair (2-3). In general, a vaginal approach is associated with lower morbidity, diminished blood loss, and postoperative bladder irritability. Furthermore, this technique may be performed in an outpatient setting. Results often equal those achieved with an abdominal approach (4). Abdominal approach is indicated when another intra-abdominal condition requires simultaneous surgical attention. This method is also used when the fistula is high lying and/or the vaginal vaults preclude a vaginal approach. Laparoscopy can be an alternative to the abdominal approach for managing VVF. Nezhat et al initially reported retrovesical laparoscopic VVF repair in 1994 (5) (Figure 2). Sotelo et al reported the largest laparoscopic series. They used a transvesical approach that led expeditiously to the fistulous tract, without the need for additional vaginal incisions or further dissection of the vesicovaginal space (6). Laparoscopy enables a limited cystotomy that has improved the historically more morbid O'Connor procedure, in which the bladder is bivalved to the level of the fistula. In general, the advantages of laparoscopy include magnification of the operative field, hemostasis, decreased hospital stay, and shorter convalescence. Recently, Sotelo et al (7) described a novel technique of VVF repair using a transperitoneal transvaginal approach, minimizing the bladder incision, which they believe it may potentially reduce recurrence rates and irritative voiding symptoms.

## DIAGNOSIS

The diagnosis of vesico-vaginal fistula can be assumed by the leakage of urine through the vagina, which may be evidenced by passing a Foley catheter into the bladder and instilling methylene blue, which will present in the vagina. Cystoscopic evaluation is imperative to know the location of the fistula. Studies have shown the benefits of vaginoscopy and cystoscopy for the evaluation (8-9). Excretory urography is essential in the preoperative evaluation, because it can differentiate between an uretero vaginal fistula and vesicovaginal fistulae.

## INDICATIONS

- Inadequate exposure related to a high or retracted fistula in a narrow vagina
- Close proximity of the fistulous tract to the ureter

- Associated pelvic pathology that requires surgery
- Multiple fistulae
- Morbid obesity
- Failure in a previous open surgical approach

## CONTRAINDICATIONS

- Generalized peritonitis
- Uncorrected or uncorrectable coagulopathy
- Patient with severe associated comorbidities from another source, contraindicating any surgical management
- Patient does not wish to be subjected to surgical management

## PREOPERATIVE PREPARATION

- As with any type of surgery, it is necessary to clearly explain to the patient the type of procedure that will be performed. It is important to address the novelty of the technique and its recent entry as a therapeutic option. Risks and complications should be discussed, as well the possibility of open surgery, owing to anatomical variations or progressive difficulty in the surgical technique. Most patients go into surgery after two

months of unsuccessful conservative management. After the failure of conservative management, the patient is maintained, if possible, without a bladder catheter until the time of the laparoscopic procedure.

- Specific patient preparation: Soft diet, at home, the evening before the procedure; antegrade bowel preparation; fasting from 22:00 hours on the day before surgery; patient admittance the day of the procedure; pre-operative administration of an intravenous (I.V.) broad-spectrum antibiotic (quinolone or cephalosporin).

## EQUIPMENT AND INSTRUMENTATION (It is the same equipment for all fistulae)

- 5-mm trocars (3)
- 10-mm trocar
- 12-mm trocar
- 5-mm atraumatic grasping forceps (2)
- 5-mm needle holders
- Hook electrocautery
- Ultrasonic Scissors
- Endoshears
- Videoendoscopy
- 10-mm 30° Laparoscope
- Cystoscope
- Carter-Thomason device
- Ureteral catheters (3) and wires
- 20F Foley catheters (2)
- 24F Foley catheter with a 70cc ballon
- 10F Blake drain
- Suction irrigator

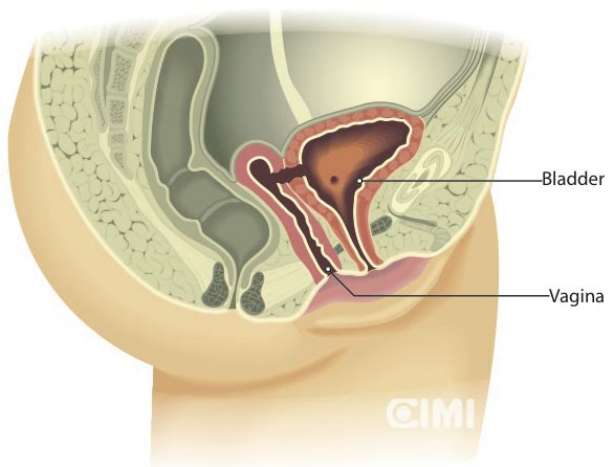


FIGURE 1.

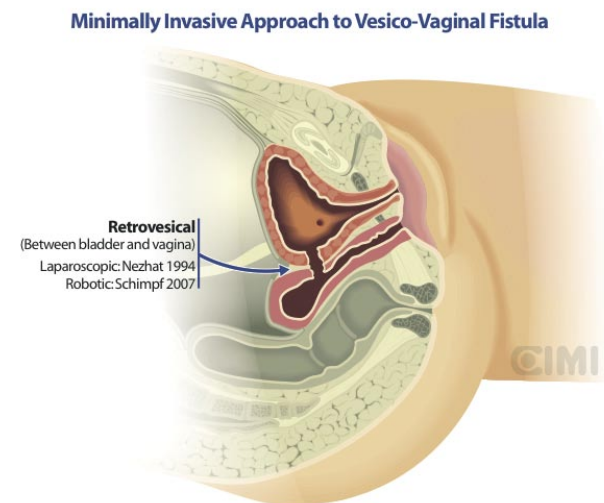


FIGURE 2.

## TRANSPERITONEAL TRANSVESICAL APPROACH (Figure 3)

### Step 1: Patient positioning

After general anesthesia is administered, the patient is placed in low lithotomy.

### Step 2: Cystoscopy and catheterization of the ureters and fistula

Cystoscopy is performed and both ureters are cannulated with 5F ureteric catheters. This facilitates identification of ureteral orifices and provides a sense of the course of the ureters. A ureteral catheter of different color is introduced through the bladder, advanced along the fistulous tract into the vagina, and retrieved at the introitus. For large fistulae, a Foley catheter can be used, instead of a ureteral catheter, through the bladder.

### Step 3: Port placement

Access is gained at the umbilicus by Hasson technique and a 10 mm port is inserted. A standard 5-port transperitoneal approach, similar to that employed in laparoscopic prostatectomy, is used.

### Step 4: Creation of omental flap, cystotomy and dissection of the fistulous tract

A sponge retractor is inserted into the vagina via the introitus. Subsequently, this is used to retract the vagina posteriorly. Once in the abdominal cavity, the first step is to set free any discovered adhesions. If there are none, we created an omental flap based off the right gastroepiploic artery, then dissection of

the posterior bladder wall is continued. A vertical incision is made, creating a small cystotomy that dissects vertically toward the fistula (Figure 4). It is important to remember that this transvesical approach leads to the fistulous tract expeditiously.

A cystoscope can be inserted and used to provide endoscopic light guidance to the fistula. However, once the bladder is opened the tract is usually visualized, because it has been catheterized. The incision is carried deep until the posterior aspect of the catheter and vaginal sponge retractor are exposed (Figure 5).

This incision can be retracted laterally in an efficacious manner. With a stitch placed at each side, and with a Keith needle or Carter-Thomason port closure needle device, the two ends of the stitch are retrieved and anchored outside of the anterior abdominal wall, obtaining adequate exposure of the fistula tract.

When communication between the vagina and bladder is apparent, the sponge retractor is withdrawn and a Foley catheter is placed in the vagina. The balloon is inflated with 70 cc to prevent loss of pneumoperitoneum. Dissection is continued until the fistula is completely separated from the vagina (Figure 6). The fibrous tissue edges of the fistula are precisely excised with laparoscopic scissors. Further dissection is performed with laparoscopic scissors to create "flaps" for adequate tension-free closure of the vagina and the bladder.

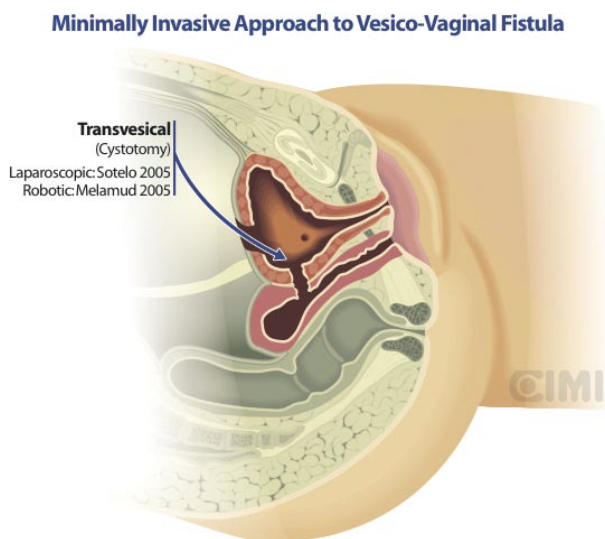


FIGURE 3.

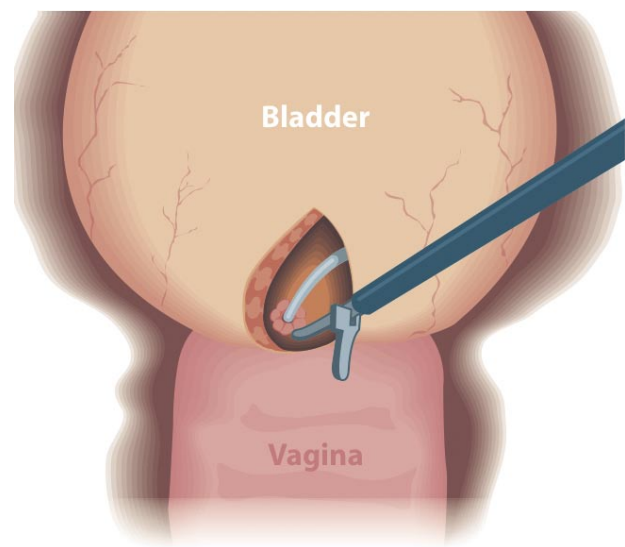


FIGURE 4.

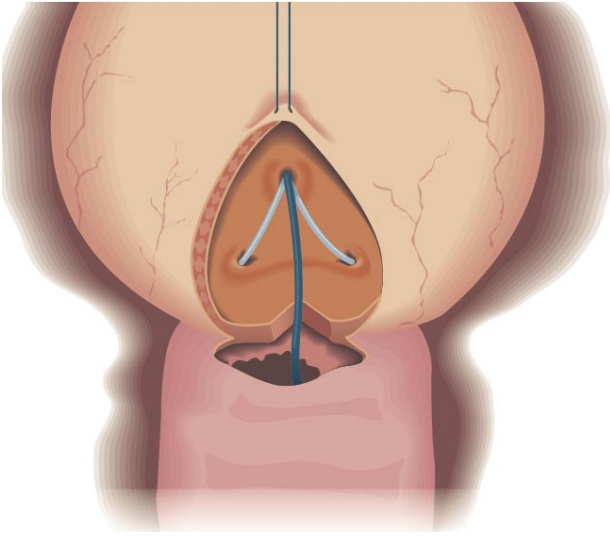


FIGURE 5.

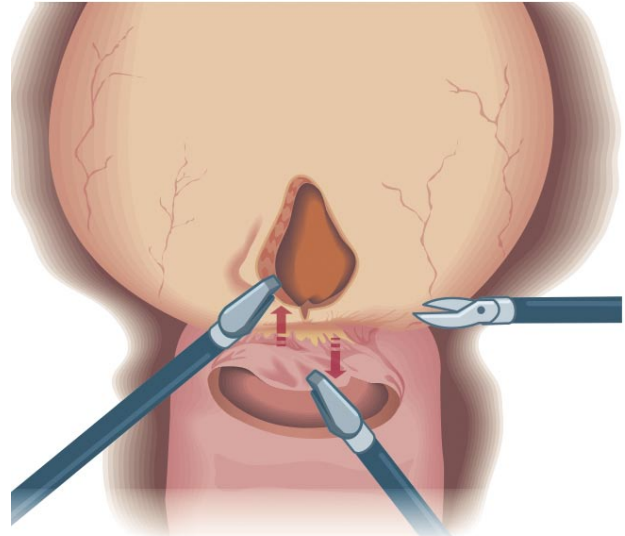


FIGURE 6.

**Step 5: Closure of the vagina and bladder and Tissue interposition**

The vagina is closed horizontally with a running 2-0 monocryl on a CT-1 needle. A suture is then placed in the anterior wall of the vagina, distal to the closure. This is used to anchor the tissue that has been harvested for interposition. Omentum, if available, or an epiploic appendix can be used (Figure 7).

The bladder is then closed vertically, beginning at the distal apex, running a 2-0 Monocryl on a CT-1 needle. The suture is run in a superior fashion. An additional running closure of the bladder serosa is performed with an absorbable suture (Figure 8).

**Step 6: Catheter placement**

The ureteral catheters are removed. A 20F urethral catheter is then inserted to maintain bladder drainage. The bladder is then filled with solution colored with methylene blue to confirm a watertight closure. A suprapubic cystostomy tube is not utilized. A drain is placed in the pelvis.

**TRANSPERITONEAL TRANSVAGINAL APPROACH** (Figure 9).

In cases of complex fistula it may be advantage to approach the fistula by incising first the vagina as opposed to the bladder, we believe that

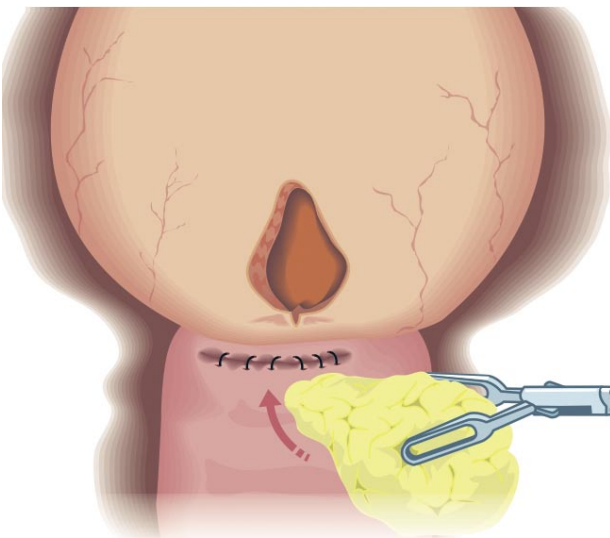


FIGURE 7.

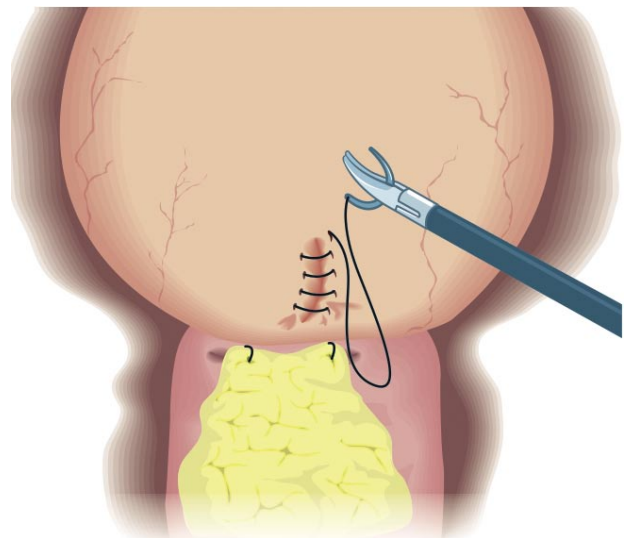


FIGURE 8.

making a small incision in the bladder, we reduce the post operative hematuria, fistula recurrence rate and irritative symptoms of the bladder.

The transvaginal approach is more feasible robotically because of the angle to the fistula from the vagina requires the endowrist. Laparoscopically, it is easier to approach the fistula from above down through the bladder

### **Step 1: Cystoscopy**

The technique includes cystoscopy and fistula identification. A 10 French Foley catheter or a ureteral catheter is placed through fistulous tract from the bladder to the vagina.

### **Step 2: Port placement**

Five port placement and releasing of previous adhesion. An omental flap is prepared and mobilized

### **Step 3:**

Stay suture is place in the bladder using a straight needle and exteriorized to maintain counter traction

### **Step 4: Incise the Vagina and excision of the fistulous tract**

The vagina is identified with digital guidance and is incised, the fistulous tract is identified with the catheter as a guide and is excised.

### **Step 5: Dissection**

The bladder and the vagina are dissected and separated.

### **Step 6: Vaginal and bladder closure, tissue interposition**

Cystorraphy is performed in two layers in an interrupted fashion using an absorbable suture. The vaginal opening is closed with running stitches. Omentum is interposed and anchored between the bladder and the vagina.

### **Step 7: Catheter placement**

A 20F urethral catheter is then inserted to maintain bladder drainage. The bladder is filled with solution colored with methylene blue to confirm a watertight closure. A suprapubic cystostomy tube is not utilized. A drain is placed in the pelvis.

## **POST OPERATIVE MANAGEMENT**

### **Immediate care**

- Two or three more doses of selected intravenous antibiotic
- Prevention of urethral catheter obstruction
- Irrigation of the bladder, only if necessary

### **Outpatient care**

- Drain removal at 2 or 3 days, as evolution
- The urethral catheter is removed 10 days postoperatively
- Oral antibiotic of choice for 10 days
- Sexual abstinence for 2 months
- Patients are advised to not use tampons

### **Minimally Invasive Approach to Vesico-Vaginal Fistula**

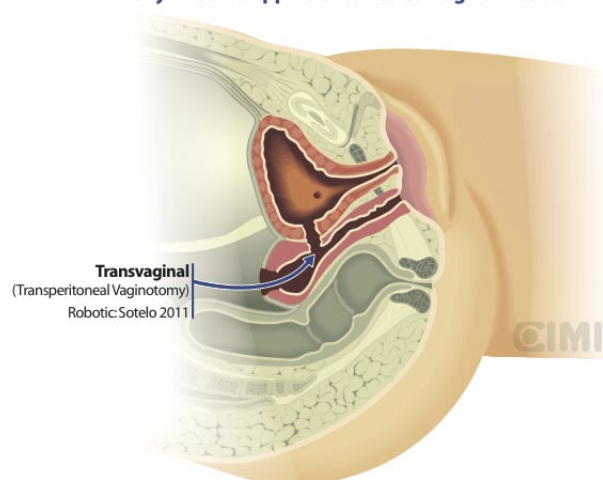


FIGURE 9.

## **URETEROVAGINAL FISTULAE**

### **INTRODUCTION**

• Ureterovaginal fistulas may occur following pelvic surgery, particularly gynecological procedures, or as a result of vaginal foreign bodies or stone fragments after shock wave lithotripsy (10). Ureterovaginal fistula has been reported following oocyte retrieval, a rare etiology of this condition (11). Patients typically presents with global and persistent urine leakage through the vagina. This causes patient discomfort, distress, and typically protection is used to stay dry. Patients may also complain of abdominal pain, fever and/or paralytic ileus (11). It is imperative to distinguish between a vesicovaginal fistula and

ureterovaginal fistula, which can coexist together in the same patient. Diagnostic approaches are described as follows.

## DIAGNOSIS

- Physical examination with speculum, where persistent urine discharge is seen through the vagina
- Filling the bladder with saline stained with methylene blue; leakage should not be seen with an isolated ureterovaginal fistula.
- Cystoscopy should be normal, with no signs of injury at the bladder
- Intravenous indigo carmine by noticing blue dye in the vagina (11).
- A ureteral catheter and a vaginal gauze can be placed, with methylene blue instillation via the ureteral catheter; staining of the gauze confirms the ureterovaginal fistula (12).
- Excretory urogram is useful in the diagnose of ureterovaginal fistulae, which can be present in complete or partial section of the ureter, in partial injuries, (Figure 10) the fistulous tract will be noticed and the contrast will reach the bladder through the partially transected ureter, not being so in complete sections of ureter where the fistulous tract will be present and the contrast wont travel the ureter beyond the injury (Figure 11).
- Renal ultrasound looking for hydronephrosis.

## MANAGEMENT

- Several techniques for the management of ureterovaginal fistulae have been described. Initial management is often conservative but typically fails. Controversy exists over the value of endourological management, with some arguing that endoscopic treatment has a high likelihood of subsequent stricture requiring surgical management. Selzman et al reported an endourological approach to ureterovaginal fistulas, including retrograde ureteral stenting, percutaneous nephrostomy or antegrade ureteral stent as an effective treatment in treating ureterovaginal fistulas (11). While short segmental defects may be managed by endoscopic manipulation, longer defects require open intervention (13).
- When conservative and/or endoscopic approaches fail, formal repair with an open, laparoscopic or robotic approach is warranted (14).
- The site of injury and the length of associated ureteral stricture usually determines the type of surgery required. When the ureteral defect precludes to direct ureteroneocystostomy, as in a thermal ureteral injury a psoas hitch, or Boari Flap reconstruction is performed. And this is due to the thermal injury requires a wide debridement because of the microvascular damage that can extend for 2 cm beyond the evidence of gross injury (15).
- Laparoscopic ureteroneocystostomy was first described by Erlich et al. and the first in an adult was reported by Reddy and Evans in 1994 (16). Implementation of laparoscopic reconstructive

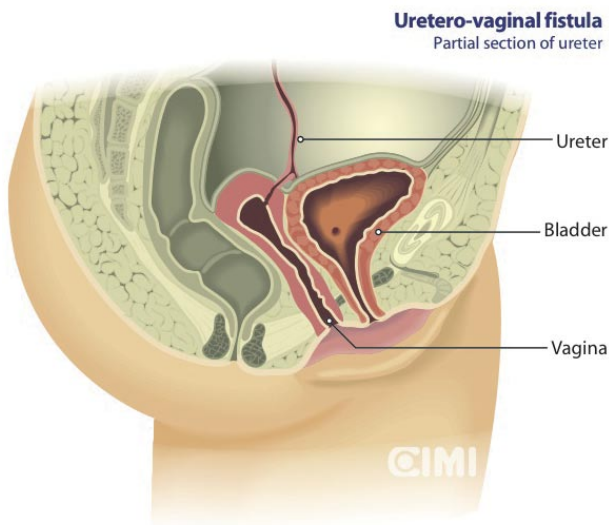


FIGURE 10.

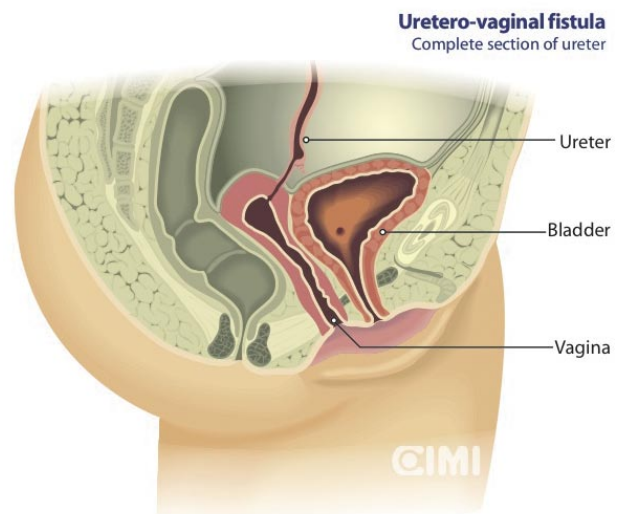


FIGURE 11.

surgery has been relatively slow because of its technical complexity and associated steep learning curve. One of the reasons for the slow progression of laparoscopic ureteric reimplantation has been the difficulty in acquiring intracorporeal suturing skills in the pelvis.

- Yohannes et al reported the first case of robotic ureteral reimplantation (17), Menon et al (18) subsequently reported a series of 3 patients who underwent robotic repair of ureterovaginal fistula with concomitant ureteral reimplantation, as described in the surgical technique that follows.

## **SURGICAL TECHNIQUE**

(Ureteral reimplantation)

- The patient is placed supine in dorsal lithotomy and in the steep Trendelenberg position. A standard six-port (robotic)transperitoneal approach is used. Following adhesiolysis, if required, the colon is then mobilized to gain access to the ureter. The ureter is traced and carefully dissected preserving its blood supply down to the level of the fistula tract and then transected. The edges of the ureter are debrided, and the ureter spatulated using robotic scissors. The bladder is distended with 200 mL of normal saline, and a cystostomy was created. The ureter is stented intracorporeally over a guide wire. The wire and stent are fed through the bed-side 5-mm assistant port. A ureteral reimplantation is performed by using a 3-0 chromic catgut suture over a 6 Fr double pigtail catheter. A Foley catheter and Jackson-Pratt drain are left in place.

## **SURGICAL TECHNIQUE**

(Ureteral reimplantation with psoas hitch)

Patil et al (13) reported 12 cases of robotic Psoas Hitch with the technique previously described by Naeyer et al (19), as follows.

- The patient is placed in a dorsal lithotomy position with a 14F Foley catheter placed in the bladder. Pneumoperitoneum is created with a Veress needle, and trocars positioned. A 12-mm camera port is placed 5 cm above the umbilicus in the midline. Two 8-mm ports are placed 3 cm above the umbilicus in the midclavicular line. A 5-mm accessory port is placed a few centimeters above the iliac crest on the opposite side of the pathology. The table is tilted to a 20° Trendelenburg position. The hemicolon is mobilized along the line of Toldt until the psoas muscle is visualized. The ureter is dissected with its blood supply preserved until the fistula segment is

encountered. The ureter is transected proximal to this segment. The urinary bladder is filled with saline to assist in freeing its lateral side. The peritoneum is incised, and the dome is mobilized until its upper portion can reach the psoas muscle without tension. The psoas muscle is exposed sufficiently to hitch the bladder. Two sutures are placed 2 cm apart to hitch the bladder to the psoas muscle. The bladder dome is incised over 7 cm and, if necessary, is kept open by two sutures placed through the abdominal wall. A submucosal tunnel is created using the robotic-assisted scissors. The ureter is pulled through the submucous tunnel by pulling on the suture with which it is tied. The ureter is spatulated and anchored deep in detrusor muscle. A non refluxing ureteroneocystostomy is created. A "double J" stent is placed in a retrograde approach. The bladder is closed in two layers with continuous sutures.

If the injury compromises the lower two-thirds of the ureter with a very long defect, which cannot be managed by the Psoas Hitch technique, ureteroneocystostomy can be made using the Boari Flap technique.

## **POST OPERATIVE MANAGEMENT**

### **Immediate care**

- Two or three more doses of selected intravenous antibiotic
- Prevention of urethral catheter obstruction

### **Outpatient care**

- Drain removal at 2 or 3 days, as evolution
- The urethral catheter is removed 10 days postoperatively
- The double J stent is removed 30 days post operatively
- Oral antibiotic of choice for 10 days

## **VESICUTERINE FISTULA**

### **INTRODUCTION**

Vesicouterine fistulae are abnormal passages between the lumen of the urinary bladder and the uterine cavity or the cervical canal (20) (Figure 12). Vesicouterine fistula is a rare condition representing only 1–4% of all urogenital fistulas (21). It is usually



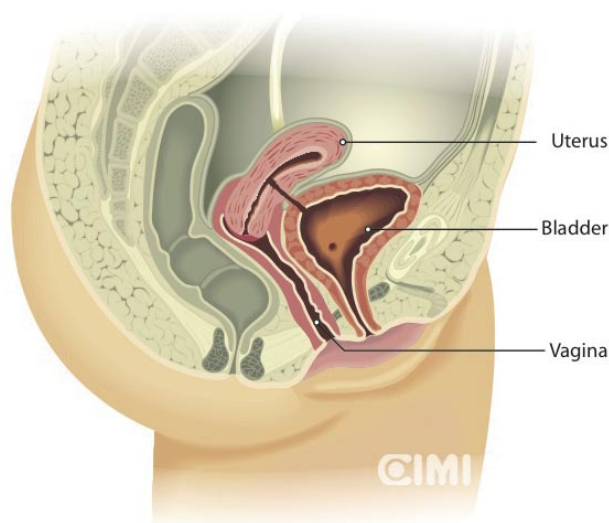
**Vesico-uterine fistula**

FIGURE 12.

reported to be related principally to cesarean section and vaginal birth after a previous cesarean section and, less often, to perforation by an intrauterine contraceptive device (22). The fistula site is typically at the posterior aspect of the bladder dome (23). The clinical presentation of vesicouterine fistulas is variable and not clearly systematized. Traditionally there have been differences between certain authors to which model best represents these type of fistulae according to the symptoms, most based on the mechanism of urinary continence (24). However, Jozwik found the pattern of menstruation to be of discriminative value. Specifically, the pattern of menstruation simultaneously reflects the degree of patency of the fistulous tract between the bladder and the uterus, and the degree of patency of the cervical canal. Consequently, the proposed division was based on two possible routes of menstrual flow at the presence of the fistula. And three types of vesicouterine fistulae could be distinguished. As shown below (25).

**Type I:** (of menouria) is characterized by the following symptoms: amenorrhea (here the term is understood as lack of vaginal menstruation), menouria (cyclical appearance of blood stained urine during the expected time for menstruation), and complete continence of urine. This triad has been known as Youssef's syndrome (26).

**Type II:** (of dual flow) is associated with the coexistence of menouria, vaginal menses, and constant or periodic incontinence of urine.

**Type III:** (of vaginal menses) is characterized by the lack of menouria, normal vaginal menstruation, and constant or periodic incontinence of urine.

**DIAGNOSIS**

Bladder instillation of methylene blue appears in vagina.

Hysterosalpingogram shows contrast between bladder and uterus.

Cystoscopy confirms a defect usually in the posterior wall of the bladder, above the trigone and their relation to ureteral meatus.

Excretory urography, to rule out other types of fistulae.

MRI confirms the fistulous tract (24).

**TREATMENT**

Treatment options depend upon fistula size, time of presentation and symptoms. Small fistulas discovered soon after surgery may close spontaneously with conservative management. A trial of bladder catheterization is warranted to allow involution of the uterus and decrease in inflammation if operative repair is contemplated (27). Hormonal treatment is based on the premise that lowering the flow of menstrual blood across the fistula may allow it to heal. Therapy involves the creation of artificial amenorrhea using either gonadotropin releasing hormone analogues or oral contraceptive pills (28). This treatment is likely to be most effective in patients with the classical Youssef syndrome. Surgery remains the mainstay of management of vesicouterine fistulas.

**SURGICAL TECHNIQUE:**

as reported by Hemal et al (29)

**Step 1:** Both ureters are catheterized with 5Fr catheters and a catheter is also placed through the fistula.

**Step 2:** Trocar placement, 1 (10mm) laparoscope, 2 (5mm) in right and left iliac fossa.

**Step 3:** Omental adhesions are freed revealing the uterus and bladder; an additional 10 mm is placed for uterus retraction lateral to the right rectus muscle at the level of the umbilicus.

**Step 4:** Cautery dissection of the peritoneum between

the bladder and uterus is performed, revealing the fistulous tract.

**Step 5:** The catheter is pulled into the peritoneal cavity and the fistulous tract is dissected until viable tissue is exposed; it is then excised using a neodymium YAG laser previous catheterization of the cervical opening.

**Step 6:** Both fistula openings are closed with interrupted 3-0 polyglactin intracorporeal sutures.

**Step 7:** Omental flap is interposed and anchored between the bladder and the uterus.

**Step 8:** A suprapubic and urethral catheter are placed for bladder drainage and removed on day 5 and 14 respectively.

## RECTOTURINARY FISTULAE

### INTRODUCTION

Rectourinary fistulae (RUF) are uncommon. Although they may develop in patients with inflammatory bowel disease and perirectal abscesses, they most frequently appear as an iatrogenic complication of extirpative or ablative prostate procedures. A review of complications after radical prostatectomy in the Medicare population revealed a 1% incidence of RUF. With ablative treatments to the prostate, RUF incidence is as follows: 0.4 - 8.8% after brachytherapy, 0 - 6% after external beam radiotherapy, and 0.4% after cryotherapy (30).

Conservative management, consisting of urinary diversion, broad-spectrum antibiotics, and parenteral nutrition, is often attempted initially; however this method typically fails. If the fistula has not closed within 3 to 6 months, it is unlikely to do so. For the management of RUF, transanal, transanorectal, trans-sphincteric, transabdominal, perineal, and combined techniques have been described. There are no data available that clearly favor one approach (31).

We will focus in the laparoscopic approach (32-34).

### DIAGNOSIS

Clinical findings suggestive of RUF include urinary infection, pneumaturia, and urine leakage per rectum (35). Imaging and endoscopic studies aid in delineating the fistulous tract. Cystoscopy,

cystography, colonoscopy, and barium enema have been used. Cystoscopy has a sensitivity of 80%-100% but combined endoscopic and radiographic evaluation affords the most precise anatomic depiction of the fistula.

### INDICATIONS

- Rectourethral fistulae
- Rectovesical fistulae

### CONTRAINDICATIONS

- The same contraindications as for any laparoscopic case.

### PREOPERATIVE PREPARATION

- Full mechanical bowel preparation the day before surgery. Enemas were used to clear the 25 cm distal rectosigmoid stump of mucous.
- Antibiotics covering enteric flora were given perioperatively.
- The patient was induced with general anesthetic.

### SURGICAL TECHNIQUE

Rectourethral fistulae (Figure 13)

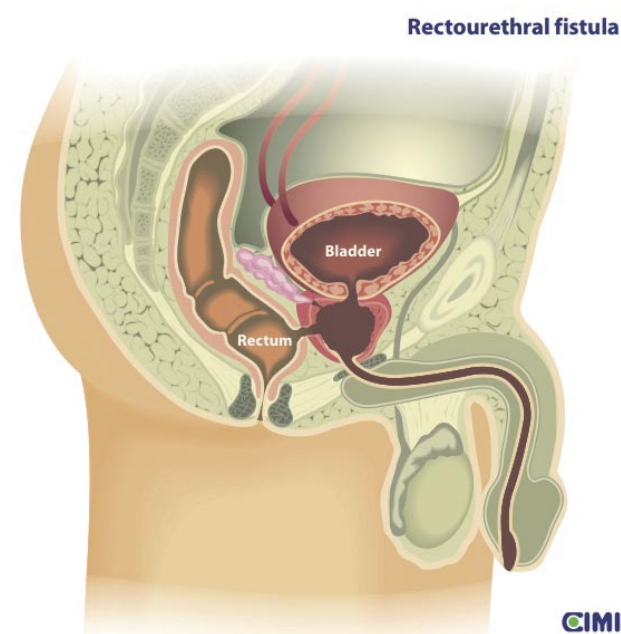


FIGURE 13.

When fistulae develop, after ablative therapies or surgery for benign prostatic hyperplasia, they form between the prostatic urethra and the rectum.

With this scenario, the surgical steps include:

**Step 1:** Excision of the remaining prostate capsule.

**Step 2:** Closure of the rectum.

**Step 3:** Tissue interposition. If a transperitoneal approach is used, then omentum is used; if an extraperitoneal approach is used, then the neurovascular bundles and periprostatic fascia are brought together in the midline.

Step 4: Urethrovaginal anastomosis is then performed in the standard fashion.

## RECTOVESICAL FISTULA (Figure 14)

When a rectourinary fistula develops after radical prostatectomy, it usually occurs along the vesicourethral anastomotic line.

### Step 1: Patient Positioning (Figure 15)

The patient is placed in a low lithotomy and steep Trendelenburg position in stirrups. Sequential compression stockings are applied to the lower extremities.

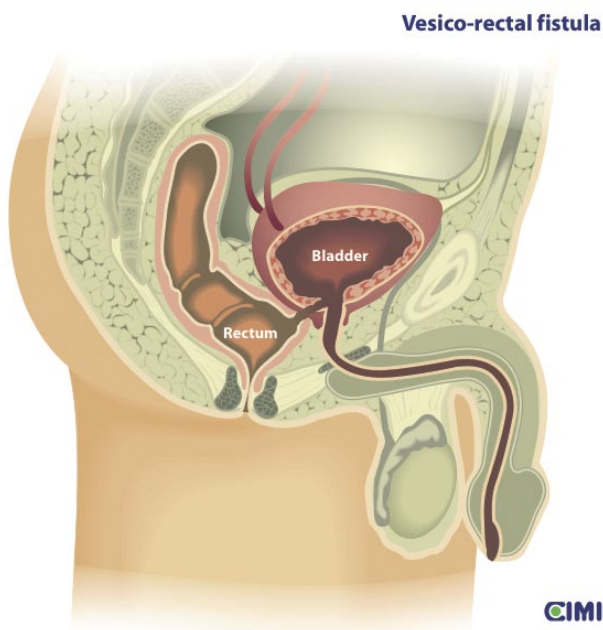


FIGURE 14.

### Step 2: Cystoscopy and catheterization of the ureters and fistula

Initially, cystoscopy is performed and both ureters are catheterized. This facilitates ureteral identification and protection during excision and closure of the fistula. A ureteral catheter, having a different color from those used for the ureters, is then pulled through the fistula into the rectum and retrieved through the anus, to facilitate identification during the excision.

### Step 3: Port placement

A five-port transperitoneal approach, similar to that for laparoscopic radical prostatectomy, is used.

The configuration could be appropriately shifted to the right or left, to avoid injuring the usually previous colostomy, when applicable. After establishing pneumoperitoneum and placing trocars, adhesiolysis is carefully performed. An omental flap, based off the right gastroepiploic artery, is created.

### Step 4: Cystotomy and dissection of the fistulous tract

A vertical midline cystotomy is created with ultrasonic shears and carried distally to the posterior aspect of the fistulous tract. This incision is continued in the direction of the catheter that defines the fistula, until the posterior aspect of the catheter is exposed.

This incision can be retracted laterally in an efficacious manner. With a stitch placed at each side, and with a Keith needle or Carter-Thomason port closure needle device, the two ends of the stitch are retrieved and anchored outside of the anterior abdominal wall, obtaining adequate exposure of the fistula tract.

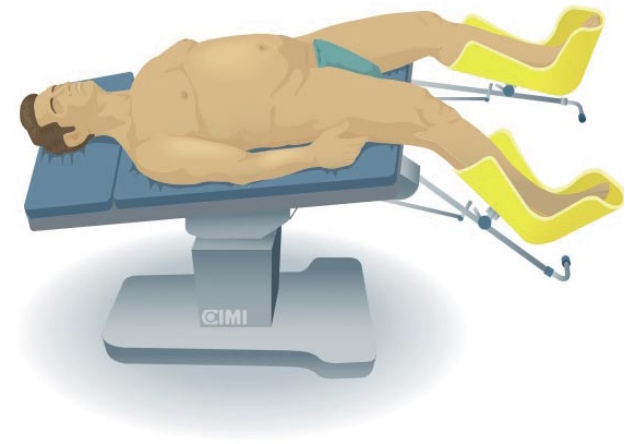


FIGURE 15.

Nonviable or necrotic tissue is precisely excised with scissors. Once communication between the bladder and the rectum becomes evident, a meticulous dissection is performed for the separation, using a combination of ultrasonic shears and laparoscopic scissors.

#### **Step 5: Closure of the rectum**

The rectal closure is then initiated. A 2-0 (Monocryl, Ethicon) on a UR-6 needle, starting with the initial knot on the outer surface of the rectum, is used for rectum closure in an interrupted one-layer technique.

#### **Step 6: Tissue interposition**

If it is long enough, intact omentum can be brought down to serve as a tissue interposition to bolster the repair. Otherwise, the ultrasonic shears can be used to make incisions to create a pedicle flap of omentum, with careful planning to preserve the vascular supply. The initial suture of the rectum closure is used to anchor the tissue interposition. In robotic surgery, the omentum flap is previously performed with laparoscopic instruments.

#### **Step 7: Closure of the bladder**

The closure is subsequently performed in one layer, using a 2-0 Monocryl suture in a running fashion. This suture is run in a superior direction. The closure is not completed until the suprapubic tube has been placed.

#### **Step 8: Cystostomy**

An extraperitoneal suprapubic cystostomy tube is placed under laparoscopic guidance. Subsequently, the closure of the bladder is completed. The bladder is filled with saline to ascertain that water tight closure has been achieved. In addition, a urethral catheter and a Blake drain are placed.

If necessary, a colostomy can be created. There is no need to reposition the patient. An abdominal exit is performed (assessing hemostasis, confirming drain location, and trocar fascial closure) in the standard fashion.

### **POSTOPERATIVE MANAGEMENT**

- It is important to maintain the patency of the urethral catheter and suprapubic tube by preventing clot obstruction and retention.
- The catheters are irrigated only if there is suspicion of an obstruction.
- Prophylactic antibiotics are administered.

- The urethral catheter and Blake drain are removed on the third postoperative day.
- The suprapubic tube is removed at two months after normal cystography.
- At four months, bowel continuity is restored with laparoscopic assistance.

### **REFERENCES AND RECOMMENDED READINGS** (\*of special interest, \*\*of outstanding interest)

1. Srichand Sachdev P, Hassan N, Mustafa Abbasi R, Madhu Das C. Genito-urinary fistula: A major morbidity in developing countries. *J Ayub Med Coll Abbottabad* 2009; 21(2)
2. Raz, S., Bregg, K., Nitti, V. and Sussman, E.: Transvaginal repair of vesicovaginal fistula using a peritoneal flap. *J Urol*, 1993; 150: 56-9
3. Blaivas, J. G., Heritz, D. M. and Romanzi, L. J.: Early versus late repair of vesicovaginal fistulas: vaginal and abdominal approaches. *J Urol*, 1995; 153: 1110-12
4. Raz, S.: Editorial comment on: Early versus late repair of vesicovaginal fistulas: vaginal and abdominal approaches. *J Urol*, 1995; 153: 1112-13
5. Nezhat, C. H., Nezhat, F., Nezhat, C. and Rotenberg, H.: Laparoscopic repair of a vesicovaginal fistula: a case report. *Obstet Gynecol*, part 2, 1994; 83: 899-901
6. Sotelo R, Mariano M B, Garcia-Segui A, Dubois R, Spaliviero, M, Keklikian W, et al. Laparoscopic repair of vesicovaginal fistula. *J Urol*, 2005; 173:1615-18.
- \*7. Sotelo R, Clavijo R, De Andrade R, Carmona, Octavio Almanzor O, Garza R, et al. Robotic repair of vesicovaginal fistulae transperitoneal transvaginal approach. *AUA video* 2012, V-1200877, Caracas, Venezuela.
8. Miller Elizabeth A, Webster George D, Current management of vesicovaginal fistulae. *Current Opinion in Urol*, 2001; 11 (4): 417-421.
9. Andreoni C, Bruschini H, Truzzi J C, Simonetti R, Srougi M. Combined vaginoscopy – cystoscopy: A novel simultaneous approach improving vesicovaginal fistula evaluation. *J Urol*, 2003; 170 (6, part 1 of 2); 2330 - 2332.
10. Hosseini S.Y, Roshan Y.M, Safarinejad M.R. Uretero vaginal fistula after vaginal delivery. *J Urol*, 1998; 160, 829
11. Selzman A, Spirnak JP, Kursh ED. The changing management of ureterovaginal fistulas. *J Urol*, 1995; 153, 626-628.
12. Mongiu AK, THelfand B, Kielb SJ. Ureterovaginal fistula formation after oocyte retrieval, *Urol*,

- 2009; 73:444.e1-444e3
13. Patil NN, Mottrie A, Sundaram B, Patel R. Robotic assisted laparoscopic ureteral reimplantation with Psoas Hitch: A multi-institutional, Multinational Evaluation.
  14. Modi P, Gupta R, Rizvi SJ. Laparoscopic ureteroneocystostomy and Psoas Hitch for post hysterectomy ureterovaginal fistula. *J Urol*, 2008; 180, 615-617.
  15. Amato JJ, Billy LJ, Gruber RP, Lawson NS and Rich NM: Vascular injuries. An experimental study of high and low velocity missile wounds. *Arch Surg*, 1970; 101: 167.
  16. Reddy PK, and Evans RM: Laparoscopic ureteroneocystostomy. *J Urol*, 1994; 152: 2057-2059.
  17. Yohannes P, Chiou RK, Pelinkovic D. Pure robot assisted laparoscopic ureteral reimplantation for ureteral stricture disease. Case report. *J Endourology*, 2003; 17 (10).
  18. Laungani R, Patil N, Krane LS, Hemal A, Raja S, Bhandari H, Menon M. Robotic- Assisted ureterovaginal fistula repair: report of efficacy and feasibility. *J Laparoendoscopic and advanced surgical techniques*, 2008; 18 (5).
  19. Naeyer GD, Migem PV, Schatteman P, et al: Pure robot assisted psoas hitch ureteral reimplantation for distal-ureteral stenosis. *J Endourology*, 2007; 21: 618-620
  - \*20. Jozwik M, Jozwik M, Lotocki W. Vesicouterine fistula, an analysis of 24 cases from Poland. *Int J Gynecol Obstet*, 1977; 57: 169-172
  21. Lenkovsky Z, Pode D, Shapiro A, Caine M. Vesicouterine fistula: a rare complication of cesarean section. *J Urol*, 1988; 139: 123-5.
  22. Ravi B, Schiavello H, Abayev D, Kazimir M. Conservative management of vesicouterine fistula: a report of 2 cases. *J Reprod Med*, 2003; 48: 989-91.
  23. Yokoyama M, Arisawa C and Ando M. Successful management of vesicouterine fistula by luteinizing hormone-releasing hormone analog. *Int J Urol*, 2006; 13, 457-459.
  24. Bonillo García MA, Pacheco Bru JJ, Palmero-Martí JL, Alapont Alacreu JM, Alonso Gorrea M, Arlandis Guzmán S, et al. Fístulas Vesicouterinas. Nuestra experiencia 25 años. *Actas Urol Esp*, 2003; 27 (9): 707-712.
  - \*25. Jozwik M, Jozwik M. Clinical classification of vesicouterine fistula. *Int J Gynecol Obstet*, 2000; 70 (3): 353-357.
  26. Youssef AF. 'Menouria' following lower segment cesarean section. A syndrome. *Am J ObstetGynecol*, 1957;73:759-767.
  27. Grasiotti P, Lambo A and Artibiani W. Spontaneous closure of vesicouterine fistula after cesarean section. *J Urol*, 1978 120: 372.
  28. Hemal A K, Wadhwa S N, Kriplani A, et al. Youssef's syndrome: an appraisal of hormonal treatment. *Urol Int*, 1994; 52: 55
  29. Hemal AK, Kumar R and Nabi G. Post-cesarean cervicovesical fistula: Technique of laparoscopic repair. *J Urol*, 2001; 165: 1167-1168.
  30. Benoit RM, Naslund MJ, Cohen JK. Complications after radical retropubic prostatectomy in the Medicare population. *Urol*, 2000; 56: 116-120.
  31. Shin PR, Foley E, Steers WD. Surgical management of rectourinary fistulae. *J Am Coll Surg*, 2000; 191: 547-553.
  32. Sotelo R, Garcia A, Yaime H, Rodríguez E, Dubois R, Andrade RD, Carmona O, Finelli A. Laparoscopic rectovesical fistula repair. *J Endourol*, 2005; 19(6): 603-607.
  33. Sotelo R, Mirandolino M, Trujillo G, Garcia A, de Andrade R, Carmona O, Sánchez L, Rodríguez E, Finelli A. Laparoscopic repair of rectourethral fistulas after prostate surgery. *Urol*, 2007; 70 (3): 515-518.
  34. Sotelo R, de Andrade R, Carmona O, Astigueta J, Velasquez A, Trujillo G, Canes D. Robotic repair of rectovesical fistula resulting from open radical prostatectomy. *Urol*, 2008; 72 (6): 1344-1346.
  35. Trippitelli A, Barbagli G, Lenzi R, et al. Surgical treatment of rectourethral fistulae. *Eur Urol*, 1985; 11:388-391.